



Camelid Dermatology in Peru

Stephen R. Purdy, DVM

Director of Camelid Studies

UMass Amherst

President Nunoa Project Peru



Learning Objectives

- ❑ To recognize the common camelid skin problems seen in field practice
- ❑ To become familiar with the diagnostic tests to identify specific etiologies if warranted
- ❑ To become familiar with treatment plans for common camelid skin problems.



Clinical Practice: Vermont and Massachusetts, 1993-2011:

Disease	Estimated Percent
Ectoparasitisms	80
Bacterial infections	10
Neoplasms, cysts, and hematomas	9
Presumed immunological disorders	1

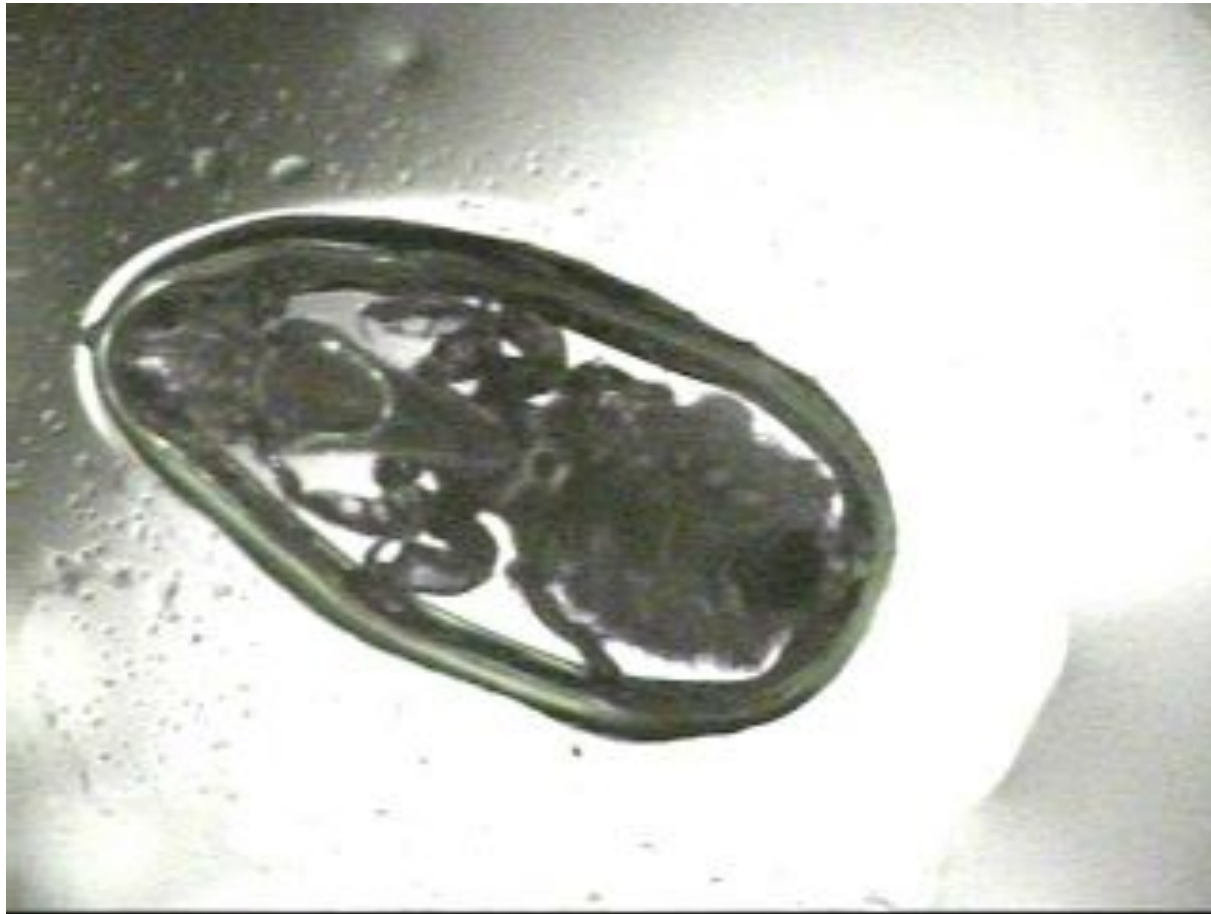External Parasites

Lice in Peru – Aug 2011



Sucking louse- *Microthoracis* spp.


Sucking louse




Lice treatment = Injectable 1% ivermectin

Mange


- *Sarcoptes*
- *Chorioptes*
- Red Mange





Sarcoptic mange- *Sarcoptes scabiei*

- not common in the US
 - Common in Peru- different appearance from chorioptic mange in the US
 - Burrows into skin
 - Clinical signs
 - Heavy white crusts in some cases
 - Strong inflammatory reaction- reddened skin

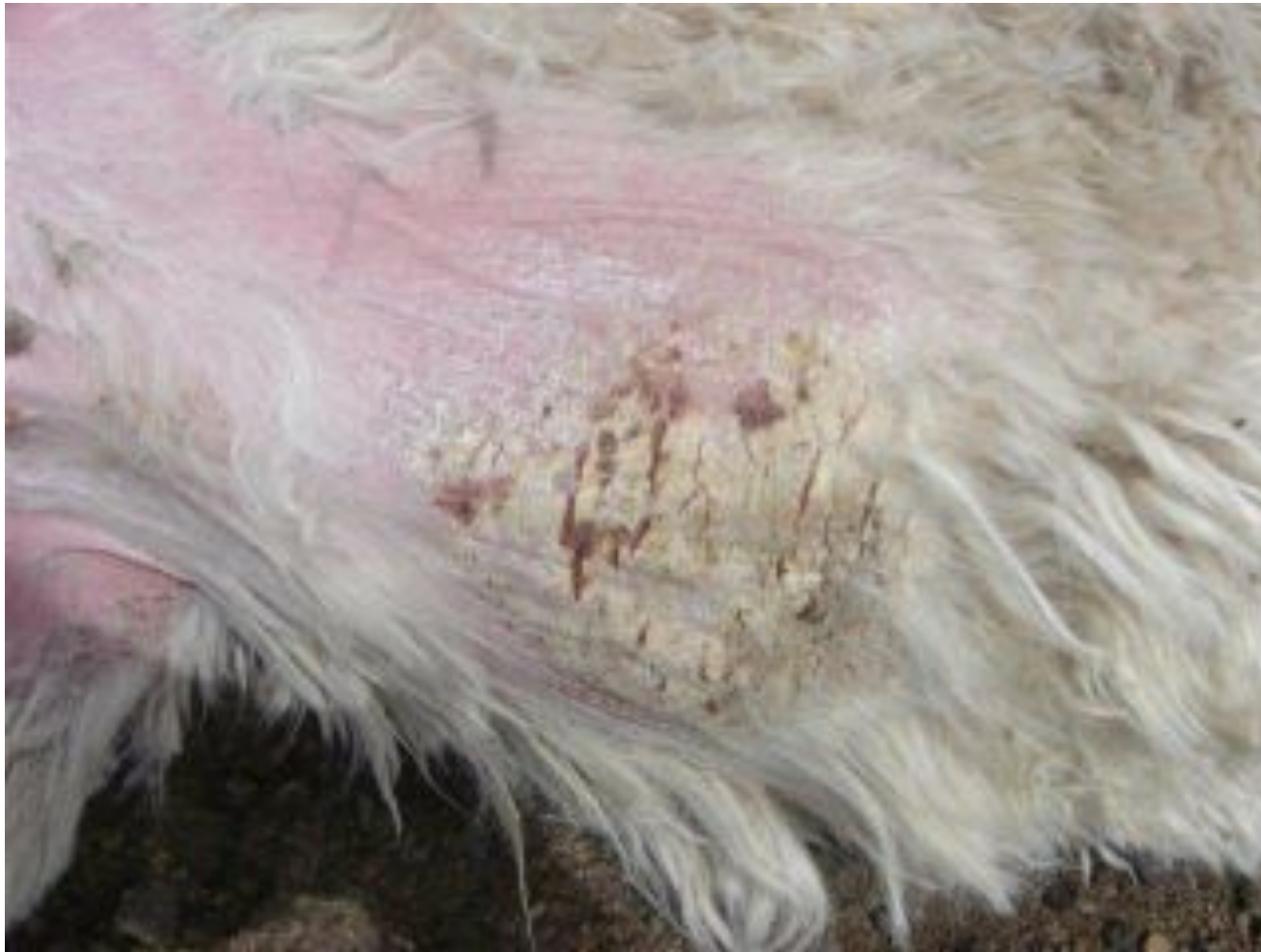- 
-
- Hair loss and crusty skin found in any or all of the following locations:
 - Inside front and rear legs
 - Inside and outside ears
 - Around eyes and on nose
 - Around anus, vulva, and scrotum
 - On lower midline and udder
 - Pasterns and between toes



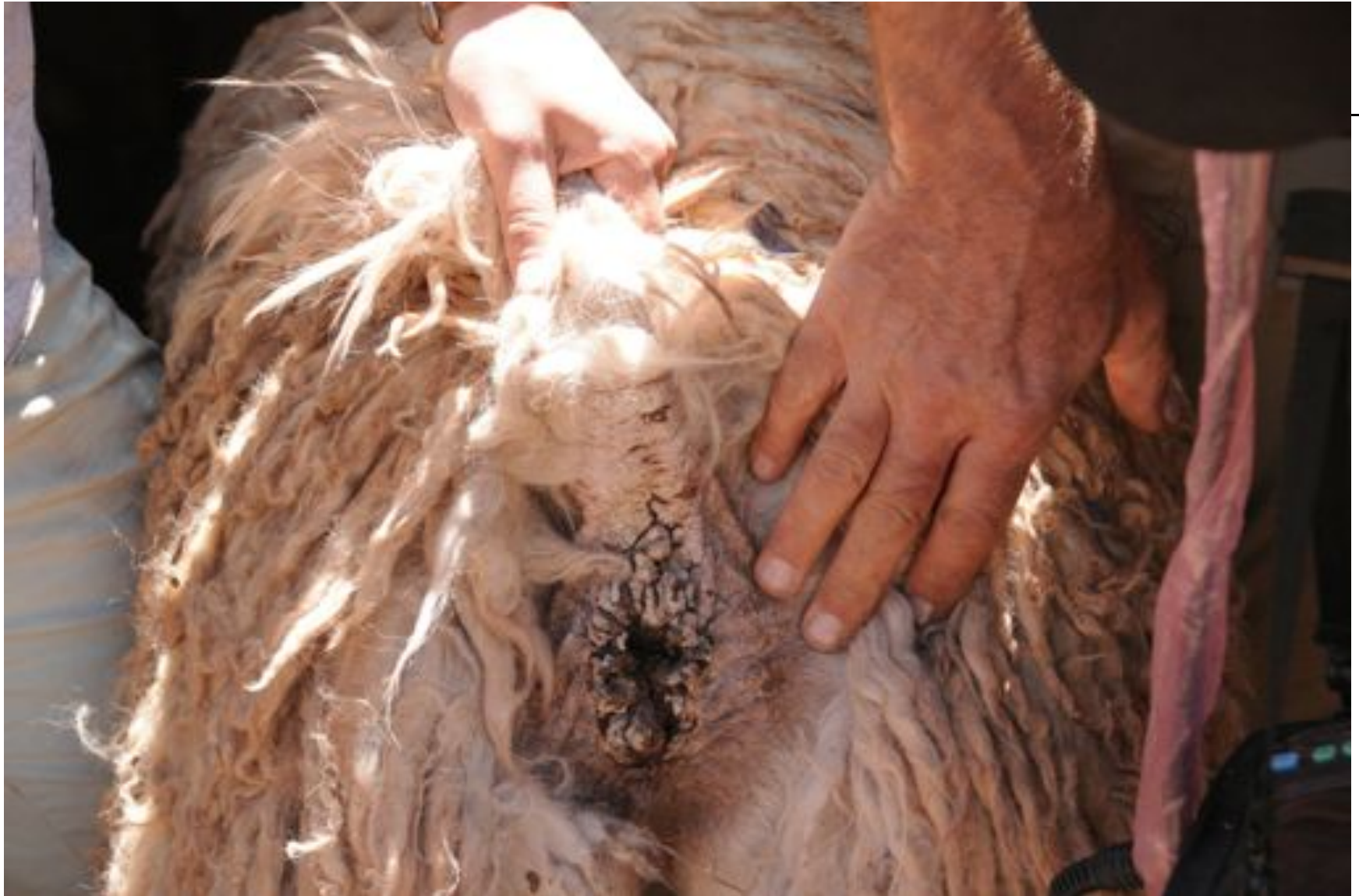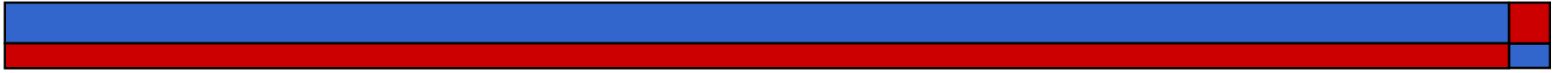
Nunoa Peru-August 2010- Mange

Group	Number Affected	Percent Affected
Adult females	18/82	22
1-2 yr. old females	8/95	8.4

Sarcoptic Mange in Peru









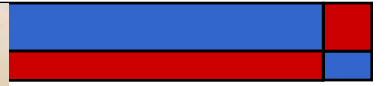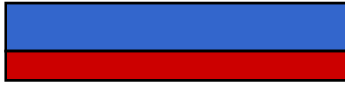- **Diagnosis** of Sarcoptic Mange

- Mites should be easy to find on skin scrapings


- **Treatment**

- **Used to respond** very well to one injection of ivermectin 1%- **What happened?**
- One application of topical petrolatum (with or without sulfa) works well there







- 
-
- May be rapidly progressive
 - Stresses often precipitate outbreaks of clinical signs
 - Malnutrition
 - Pregnancy
 - Social changes
 - Supposedly contagious but usually only a small percentage of the herd is affected
 - Other animals may be unapparent carriers



□ **Diagnosis of Chorioptic Mange**

- Not found in Nunoa to date
- Characteristic clinical signs ~ sarcoptic mange
- Response to treatment
- Skin scrapes often miss the mites
 - Between the toes is reported to be the best area to scrape
 - Can find mites there in **clinically normal animals**
 - **Whole herd foot treatments?????**
 - May be hidden under infected and inflamed skin




Chorioptic Mange Treatments

- ❑ Old and **not effective now**- 2x dose ivermectin 1% injection subQ weekly for 4 weeks
- ❑ Topical Cydectin® or Eprinex® Pour On applied right onto the skin through the fiber weekly 3 or 4 times
- ❑ Injectable Cydectin® at the cow dose
- ❑ Tar and sulfur shampoo to help remove crusts if needed

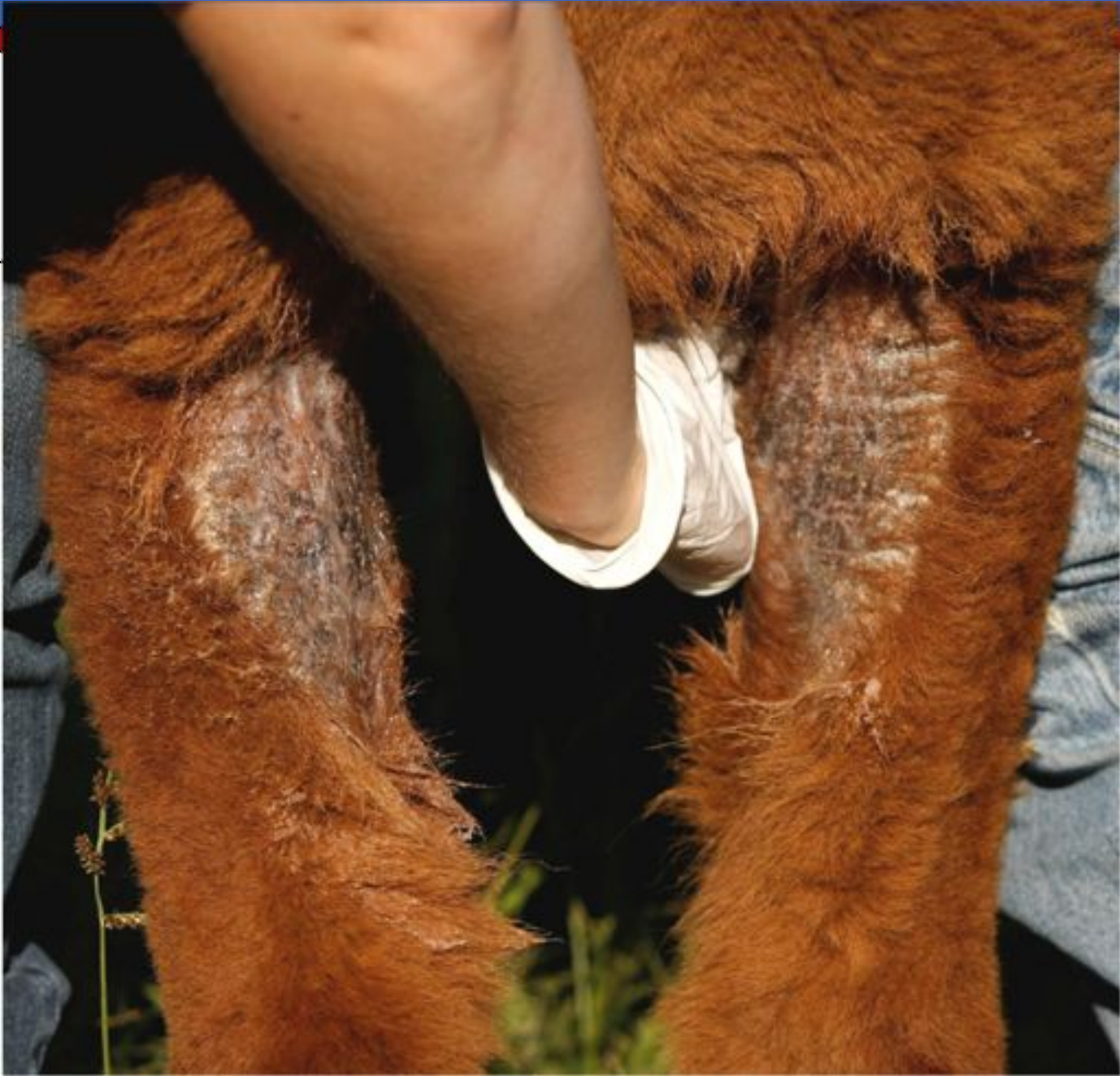

□ **Other reported “cures”**

- Tea tree oil?
- Bag Balm®- works!
- ivermectin, antibiotic, DMSO, and mineral oil combinations?
- topical treatment with diluted Frontline®?

- 
-
- **My current favorite = petrolatum**
 - Petroleum jelly (Vaseline®)
 - Do not get it in the eyes
 - Loosens the crusts
 - Has cleared up even chronic cases

 - **Extensively damaged skin may not ever fully recover!**

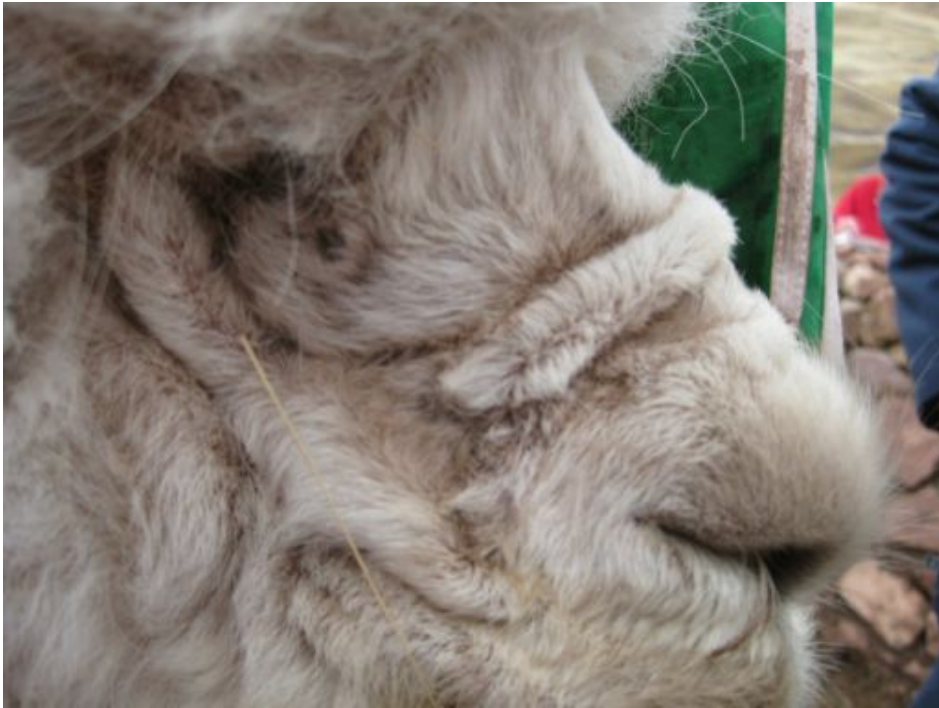

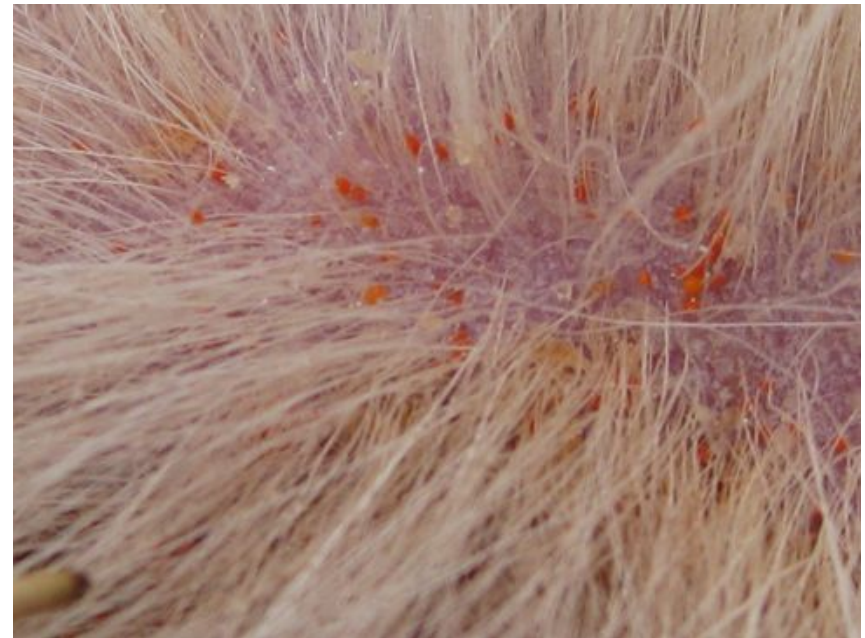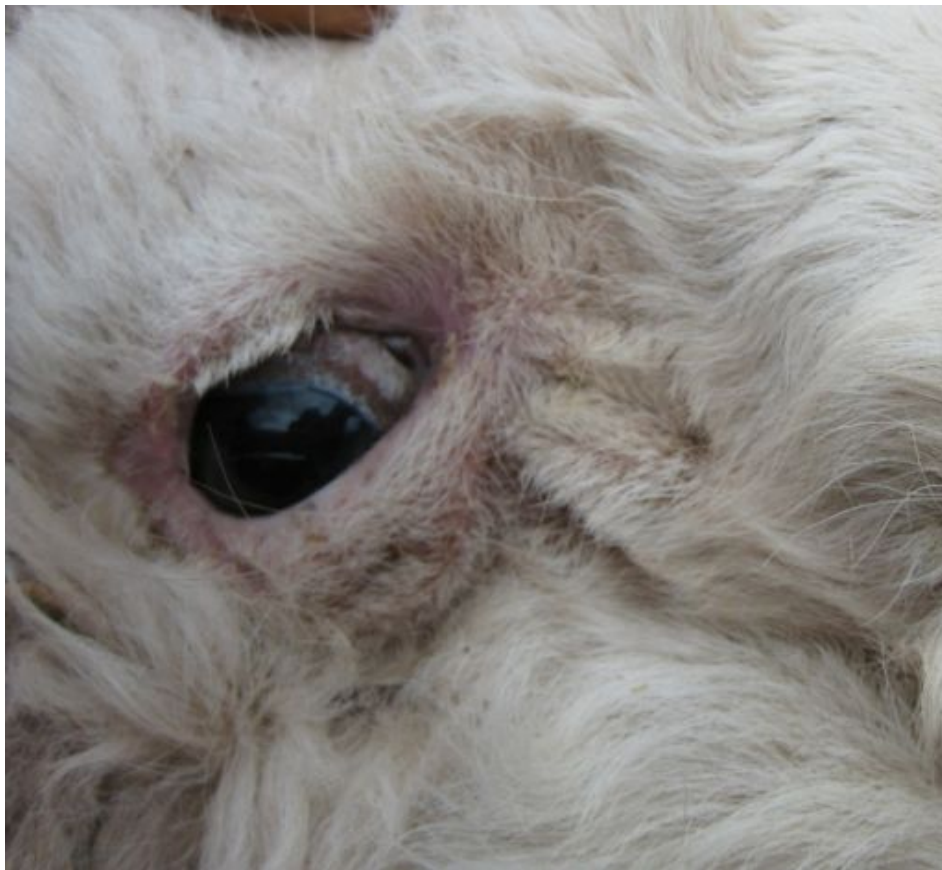Red mange- red mites- chiggers

Eutrombicula sp.- Trombiculosis



Chronic cases







Bacterial and Fungal Skin Infections

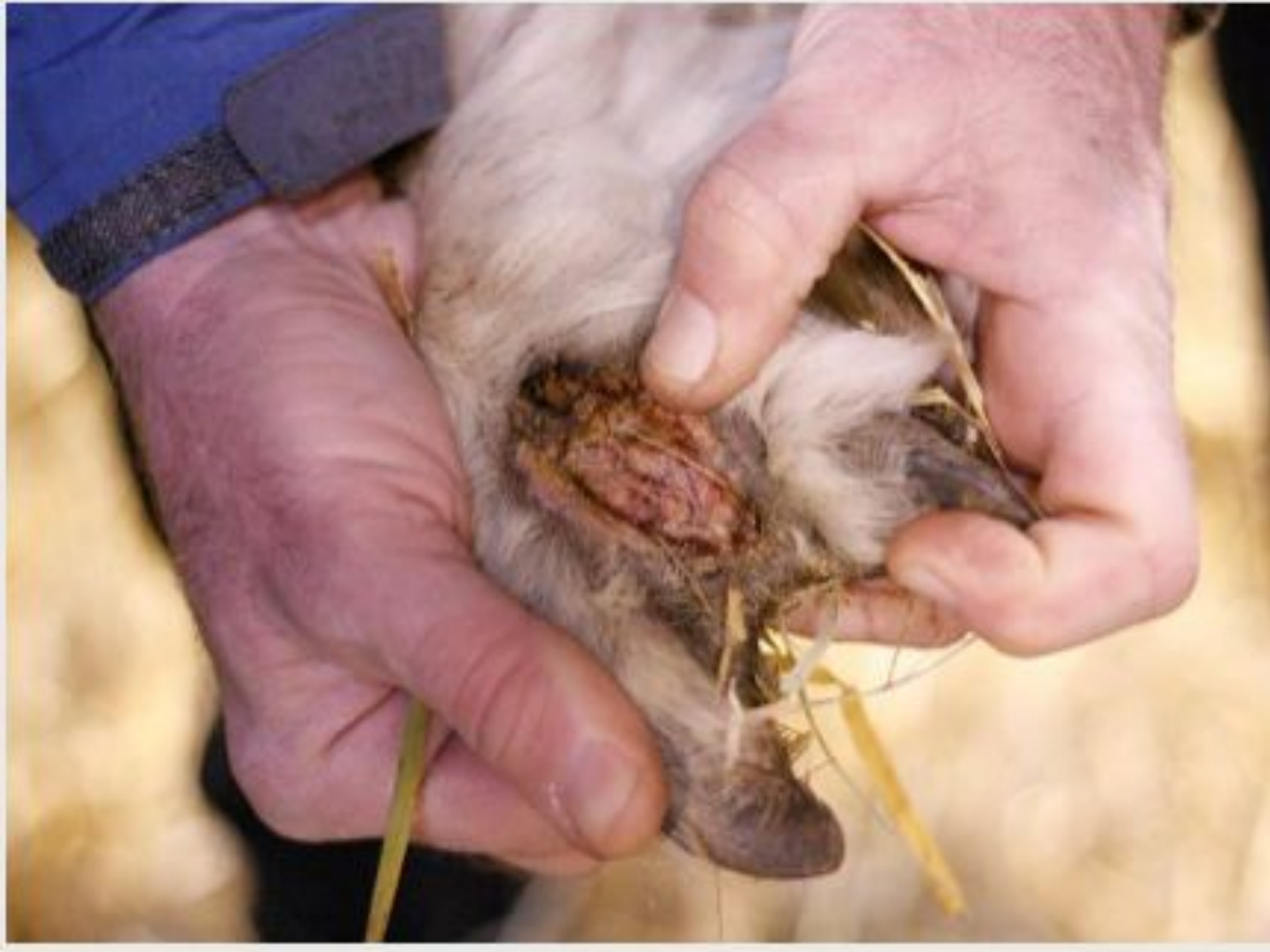- ❑ Uncommon in my practice area
- ❑ Immune system malfunction??
- ❑ Topical and/or systemic treatment as indicated
- ❑ Antibiotics, remove hair, topical Iodine scrubs to cleanse and apply iodine ointment

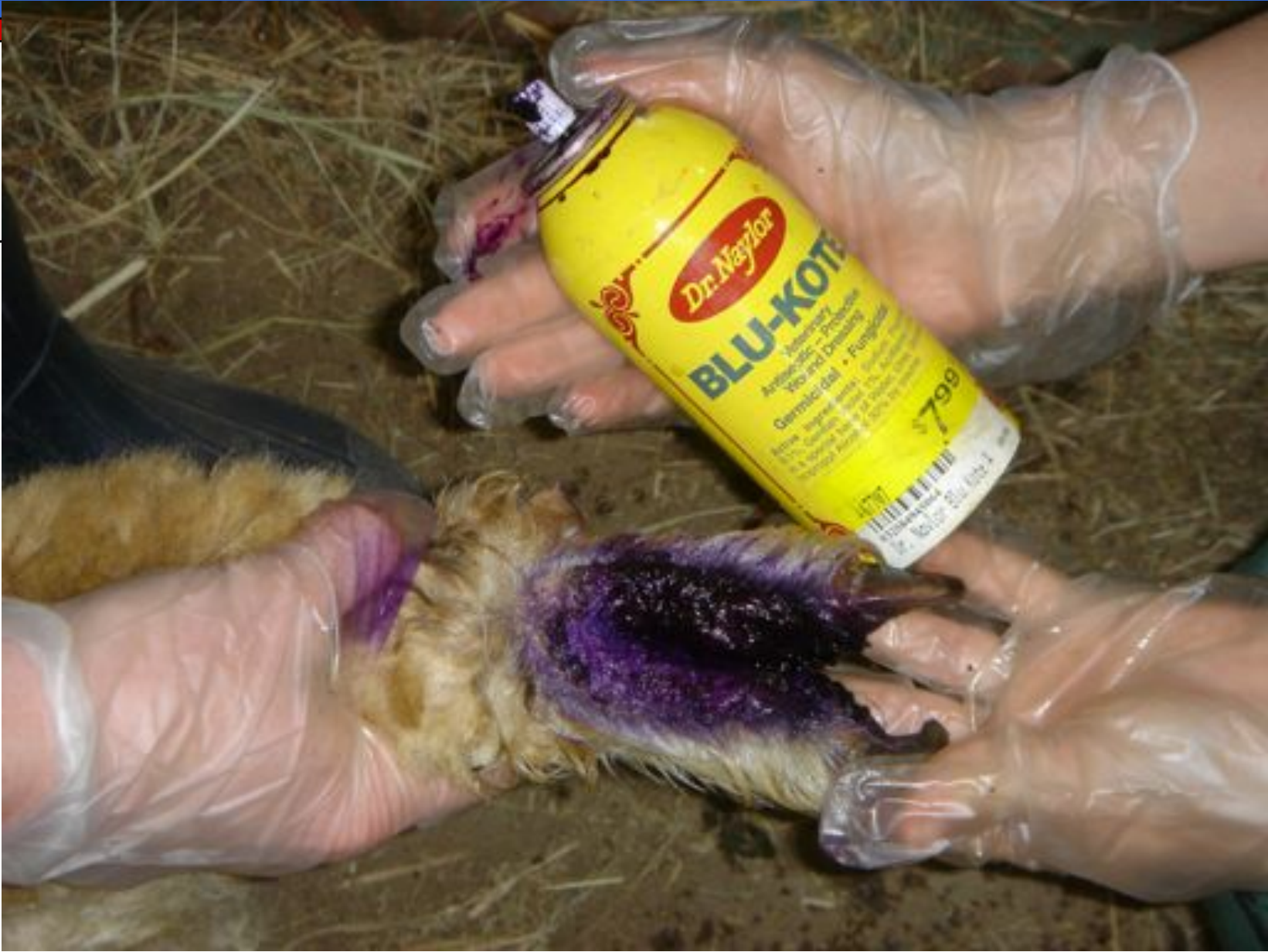

Camelid Foot Diseases

- Categories
 - infections
 - bacterial/fungal
 - foreign body
 - solar necrosis/abrasion
 - neoplasms

Foot infections







□ Etiology

- most are a result of poor environmental conditions
- fungal and bacterial organisms are involved
- fecal contamination and wet conditions are predisposing causes
- may not be discovered until shearing or show time in the spring/summer

□ **Foreign Bodies**

- usually associated with lameness
- thorns, nails, sticks



□ **Diagnosis**

- physical appearance
- microbial culture and sensitivity not often used in field practice


□ **Clinical signs**

- lameness not common unless a foreign body is involved
- one or multiple feet involved
- bad odor
- purulent discharge/exudate
- granulation tissue present on dorsal surface of foot between the digits



□ Treatment

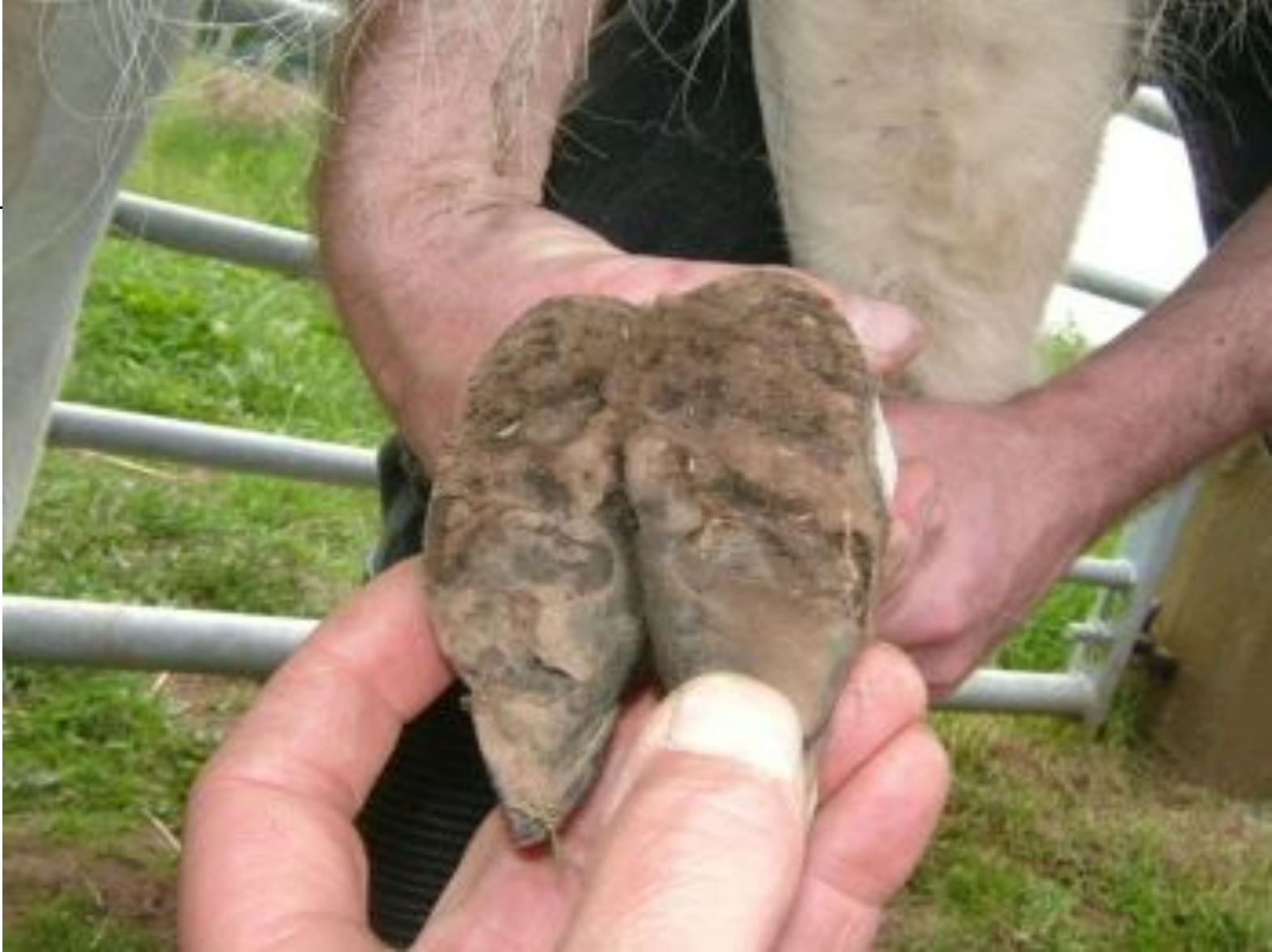- topical cleaning with disinfectants- iodine scrub, chlorhexidine scrub
- topical ointments or sprays
 - Biozide®
 - Nolvasan®
 - BluKote®

- 
-
- wrapping?
 - systemic antibiotics
 - Nuflor®- 6.0 ml/ 100 lb. SQ every 3 days
 - long acting oxytetracycline @ 9 mg/lb SQ every 3 days
 - may also be used topically
 - improve the environment



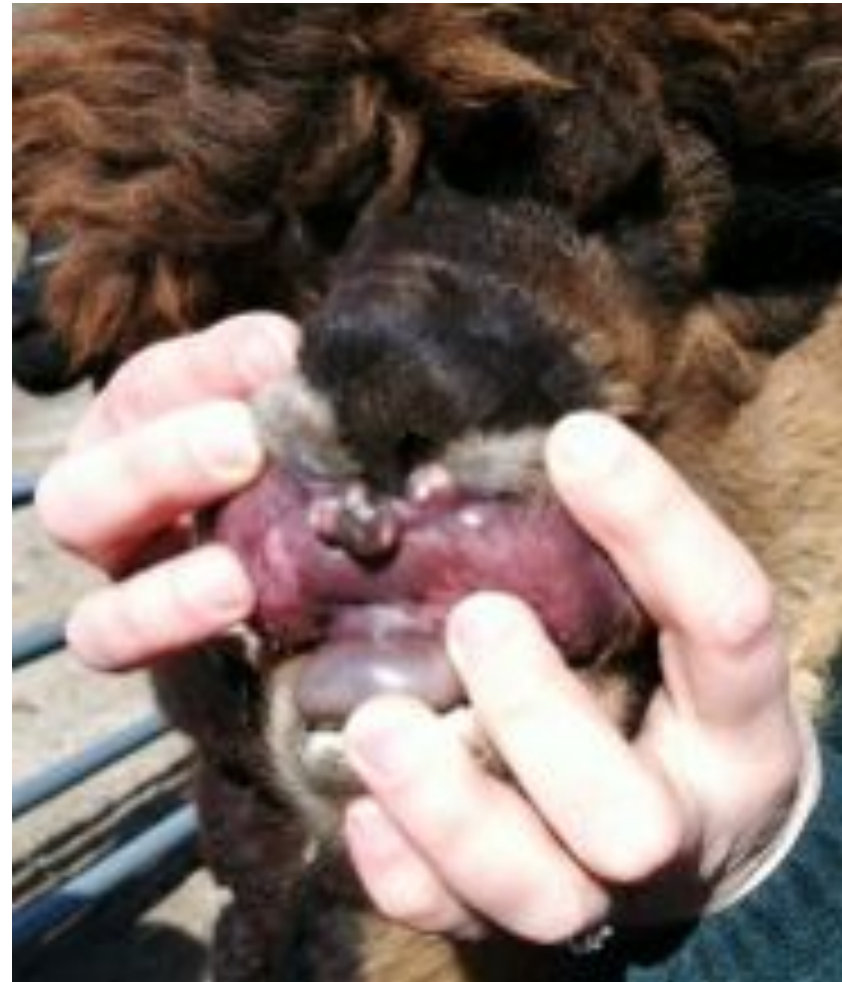Sole necrosis/abrasion

- Etiology unclear
 - Suspect exposure to wet and unclean conditions
- Most often an incidental finding at nail trimming time
- Treatment
 - Remove loose sole tissue
 - House in a clean environment



Neoplasms


- **Fibromas**
 - uncommonly seen on feet on pasterns
 - Also seen on the face near nostrils
 - Remove by cutting off flush with the surrounding skin (and wrapping if possible until healed)





□ Squamous cell carcinoma

- at the site of the ventral callus on the sternum in 1 case
- Appeared as granulating wound with maggot infestation in early summer
- Topical treatment and debridement was not successful
- After 2 debridements tissue was submitted for histopath and diagnosis was made

- 
-
- 15 year old gelding in deteriorating body condition
 - BCS 1 of 5 in summer
 - Progressive distension of the abdomen also seen
 - No post mortem exam possible unfortunately